

CLINICAL IMAGE

RARE SKIN LESION ON A NEWBORN

Alicia Yin, OMS-IV¹; Mackenzie Jensen, OMS-IV¹; Edifel Macatuno, MD, FAAP²;
Hanna Sahhar, MD, FAAP, FACOP²

¹Edward Via College of Osteopathic Medicine-Carolinas Campus, Spartanburg, SC

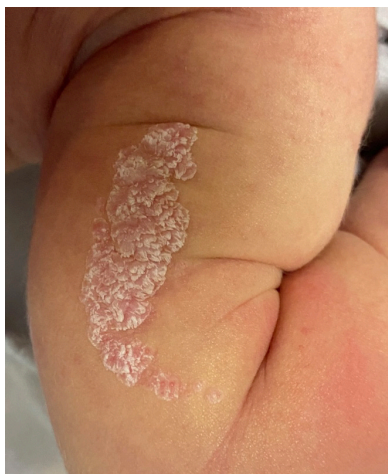²Spartanburg Regional Healthcare System, Department of Pediatrics, Spartanburg, SC

CASE REPORT

A newborn female was evaluated in the well-baby nursery after she was born full term at 39 weeks' gestation via C-section to a 37-year-old G2P2 mother. There was no history of sexually transmitted infections during pregnancy or genital lesions prior to delivery. However, the delivery was complicated by maternal positive Group B streptococcal (GBS) status, for which the mother received one dose of cefazolin before delivery. The newborn patient was found to have hyperbilirubinemia and was admitted to the hospital for 2 days for phototherapy treatment. Her newborn exam was unremarkable except for jaundice and a linear, silvery-white, scaly lesion to the left upper extremity (Figure 1). The family history was negative for dermatologic conditions. The baby was otherwise asymptomatic with appropriate feeding and bowel movements. Her stay was uneventful, and she was discharged without complication.

FIGURE 1:

During the newborn's physical exam, raised silvery-white skin plaque was found on the left upper arm.



CORRESPONDENCE:

Alicia Yin, OMS-IV | yin.alicial@gmail.com

Copyright© 2024 by the American College of Osteopathic Family Physicians. All rights reserved. Print ISSN: 1877-573X doi: 10.33181/160205

The authors have no conflicts of interest or financial disclosures.

This lesion was followed at the patient's subsequent 2-month well-child check and is depicted in Figure 2, with gradual changes noted in the lesion. Figure 3 shows the continuation of hyperpigmentation and verrucous transformation of the skin lesion at the 4-month well-child check. The patient was referred to dermatology for a definitive diagnosis and discussion of potential treatment options.

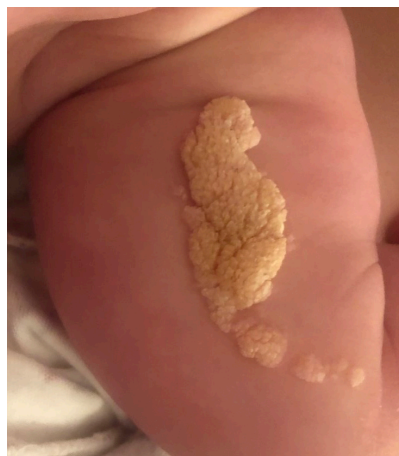
FIGURE 2:

The left upper arm skin lesion appears at the 2-month well-child check with progressive lesion hyperpigmentation and verrucous characterization.

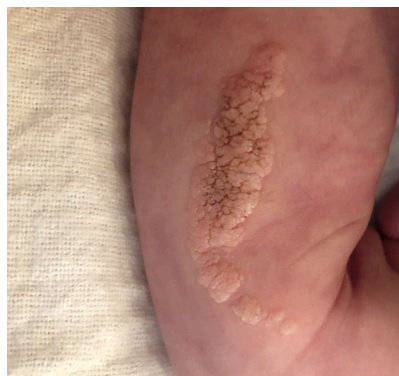

FIGURE 3:

Further evolution of the skin lesion was seen at the 4-month well-child check with deepening hyperpigmentation and verrucous transformation. A dermatology referral was made at this visit.



QUESTIONS

1. What is the most likely diagnosis?

- a. Linear psoriasis
- b. Epidermal nevus
- c. Lichen planus
- d. Lichen striatus
- e. Linear porokeratosis

Correct answer:

b. Epidermal nevus

Linear verrucous epidermal nevus (LVEN) is a benign dermatologic skin lesion that is well-demarcated from surrounding skin and has a verrucous or wart-like appearance. The lesion may appear skin-colored early in development but gradually darkens over time. The lesion may grow and plateau around the time of adolescence. The distribution of lesions varies from solitary papules to multiple plaques.

Differential diagnoses of epidermal nevus include linear psoriasis, lichen planus, lichen striatus, and linear porokeratosis, which all typically follow the same distribution but have different appearances. Psoriatic lesions are more common in adults and have an erythematous base with an overlying silver scale. Lichen planus lesions present as violaceous flat-topped papules. Lichen striatus lesions are triggered by infection, trauma, or other environmental causes. They are pink or dull red scales that last a few weeks to months before resolving spontaneously without any residual complications. Lesions of linear porokeratosis are red and have a raised edge with a furrow or atrophic center. Observation of this newborn's lesion over several months allowed for eliminating many of the differential diagnoses and was most consistent with the presentation of a LVEN. upper abdomen, a 1.1-cm perirenal nodule was also appreciated.

In light of these findings, hematology-oncology specialists and infectious disease specialists were consulted, and a nodule biopsy was obtained from the patient's right shoulder by interventional radiology.

2. Aside from the integumentary system, what other body systems may be involved with this diagnosis?

- a. Nervous
- b. Vascular
- c. Musculoskeletal
- d. All of the above
- e. None of the above

Correct answer:

d. All of the above

Epidermal nevi result from mutations in genes responsible for epidermal cell growth and development. The earlier these mutations occur, the more extensive the disease may be and the more body systems affected. Some examples of extensive systemic involvement include epidermal nevus syndrome (ENS); congenital hemidysplasia with ichthyosiform erythroderma and limb defects (CHILD) syndrome; and congenital lipomatous overgrowths, vascular malformations, epidermal nevi, and scoliosis/skeletal/spinal anomalies (CLOVES) syndrome. Clinical manifestations of these syndromes include seizures, developmental delay, hemiparesis, cranial nerve palsies, deafness, cataracts, scoliosis, ipsilateral hypoplasia of limbs, unilateral alopecia, severe nail dystrophy, Wilms tumor, vascular malformations, scoliosis, spina bifida, macrodactyly, and sandal gap deformity.^{2,3} Identifying epidermal nevi is important because they can be associated with abnormalities in one or more different organ systems in 33% of patients.⁴

DISCUSSION

LVEN are rare skin findings in one to three out of 1000 people.² They are thought to occur due to sporadic postzygotic mutations leading to mosaicism in genes associated with skin cell growth, differentiation, and division. Some commonly affected genes include fibroblast growth factor receptor (FGFR3), phosphatidylinositol 3 kinase (PI3K), and RAS oncogenes, specifically HRAS.^{2,3} Furthermore, timing of the mutation also plays a role in the severity of the condition. The earlier during embryologic development the mutation occurs, the more likely the nevus is to be associated with extensive systemic involvement.^{2,3,6}

Classically, an LVEN is linear in configuration and develops along the lines of Blaschko, representing lines of normal skin development and migration, which become evident in those with mosaic skin conditions. It is most commonly seen at birth or in early childhood. The lesions are often found unilaterally on the trunk or extremities, although they can develop on the head, neck, or oral cavity. The nevi themselves are raised and may initially be pink but will often darken to a brown color with time. Occasionally, they may be associated with pruritus or tenderness.⁴

LVEN diagnosis is usually made clinically based on the presentation and appearance of the lesion. However, it can be confirmed definitively via histopathology, which shows marked hyperkeratosis, acanthosis, and papillomatosis of the epidermis.²

There is no single recommendation regarding treatment for LVEN, as treatment regimens will depend on the lesions specifically. Surgical excision may be considered for smaller lesions due to lower risks for recurrence and scarring. Larger lesions are more difficult to treat due to scarring risks with surgical excision and varying responses to laser ablation, topical therapies, and light therapy.⁵

Early diagnosis, treatment, and intervention are crucial to supporting patients with LVEN. In rare instances, lesions can undergo malignant transformation to basal or squamous cell carcinoma. Identifying these lesions and investigating the specific

associated syndromes can guide treatment plans and referrals to include ophthalmology, neurology, and possibly plastic surgery for surgical excision of the lesion, depending on the extensiveness and location of the lesion.

SUMMARY

In this case, epidermal nevus was diagnosed clinically based on its resemblance to characteristic LVEN lesion presentation and progression. Before diagnosis by dermatology, the parents reported the plaque was erythematous and inflamed but noted that they had been applying coconut oil as a moisturizer, which seemed to help with inflammation. Therapeutic options were discussed with the parents, including surgical excision, laser ablation, and topical therapies. After much deliberation, the parents decided to conduct a clinical observation of the lesion for now. They would consider a referral to plastic surgery for laser resurfacing at a later age. The parents were advised to continue moisturization with coconut oil and to arrange a follow-up appointment if the skin lesion worsens. The patient has tolerated this supportive therapy thus far and continues to do well.

REFERENCES

1. Bajaj A. Verrucous and inflammatory epidermal nevus. *Open Access J Surg.* 2020;11(2):555808. doi: 10.19080/OAJS.2020.11.555808
2. Garcias-Ladaria J, Cuadrado Rosón M, Pascual-López M. Epidermal nevi and related syndromes – part 1: keratinocytic nevi. *Actas Dermo-Sifiliográficas (Engl Ed).* 2018;109(8):677-86. doi: 10.1016/j.adengl.2018.07.019
3. Paller AS, Mancini AJ. (2022). Chapter 9: Cutaneous tumors and tumor syndromes. In: *Hurwitz Clinical Pediatric Dermatology*; 2022.
4. Rogers, Maureen, Ian McCrossin, and Christopher Commens. 1989. Review of Epidermal Nevi and the Epidermal Nevus Syndrome. *American Academy of Dermatology* 20 (3). [https://doi.org/10.1016/S0190-9622\(89\)70061-X](https://doi.org/10.1016/S0190-9622(89)70061-X).
5. Wright TS. Epidermal nevus and epidermal nevus syndrome. UpToDate. <https://www.uptodate.com/contents/epidermal-nevus-and-epidermal-nevus-syndrome>.
6. Kim R, Marmon S, Kaplan J, Kamino H, Pomeranz MK. Verrucous epidermal nevus. *Dermatol Online J.* 2013;19(12):20707. doi: 10.5070/D31912020707
7. Gupta A, Rai R. Linear verrucous epidermal nevus. *Indian Pediatr.* 2019;56(11):981.